DOI: 10.7860/JCDR/2025/81056.21590

Case Report

Surgery Section

Infraclavicular Spindle Cell Haemangioendothelioma Mimicking Peripheral Nerve Sheath Tumour: A Case Report

ASHISH JIVANI[1], RAJU SHINDE[2], SANGITA JOGDAND[3], DHWANI MAVANI[4], APOORVA PANDE[5]

(cc) BY-NC-ND

ABSTRACT

Haemangioendotheliomas are rare vascular tumours that exhibit a biological spectrum intermediate between benign haemangiomas and highly malignant angiosarcomas. The malignant variant, Spindle Cell Haemangioendothelioma (SCH), typically presents in soft tissues and is particularly uncommon in the infraclavicular region. Hereby, the authors present an unusual case of SCH, initially misdiagnosed as a nerve sheath tumour, and successfully managed with surgical excision. A 32-year-old female presented with progressive swelling of the right upper limb for the past six months, along with a mass in the right infraclavicular region that had been enlarging for four months. Imaging studies suggested a Peripheral Nerve Sheath Tumour (PNST), and a Tru-cut biopsy indicated a benign spindle cell lesion. Surgical excision was performed, and Histopathological Examination (HPE) confirmed the diagnosis of haemangioendothelioma (spindle cell subtype). The postoperative course was uneventful, and Adjuvant Radiotherapy (RT) was initiated due to positive tumour margins. RT was well tolerated, and the patient was asymptomatic at the six-month follow-up. Thus, although rare, malignant haemangioendothelioma should be considered in the differential diagnosis of soft tissue masses near vascular structures.

Keywords: Adjuvant radiotherapy, Bone erosion, Neurofibroma, Spindle cell haemangioma

CASE REPORT

A 32-year-old female presented with complaints of painless swelling in the right upper limb for the past six months, accompanied by a progressively enlarging mass in the right infraclavicular region for the last four months. The swelling was insidious in onset and gradually increased in size. She also reported occasional tingling and numbness in the right upper limb, particularly around the elbow. There was no significant medical history. Conservative management did not provide symptomatic relief.

Local examination revealed a firm, non tender lump measuring 5×3 cm in the right infraclavicular region, extending from the lower margin of the clavicle to the upper right axillary tail of the right breast. The lump was smooth and mobile, without erythema, pulsations, or skin changes. Ultrasonography of the abdomen and pelvis was unremarkable. Magnetic Resonance Imaging (MRI) of the chest revealed a lobulated mass in the right infraclavicular region, suggesting a nerve sheath tumour. This was further supported by a local site ultrasound that identified a PNST. No evidence of bone erosion or distant metastasis was noted.

A Contrast-enhanced Computed Tomography (CECT) scan of the thorax demonstrated a large, well-defined, heterogeneously enhancing soft tissue mass in the right infraclavicular region [Table/Fig-1]. The lesion displayed anterior extension abutting the right pectoralis minor muscle, with focal loss of fat planes, posteromedially abutting the intercostal muscles, also with focal loss of fat planes, and posteriorly compressing the right subclavian artery, while fat planes with the subscapularis muscle were maintained [Table/Fig-2]. A Tru-cut biopsy confirmed the presence of a benign spindle cell lesion consistent with neurofibroma.

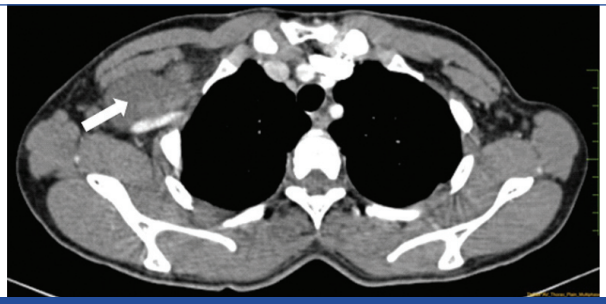

[Table/Fig-1]: Axial CECT image showing a well-defined, heterogeneously enhancing soft-tissue mass in the right infraclavicular region, abutting the subclavian artery and pectoralis minor with focal fat plane loss.

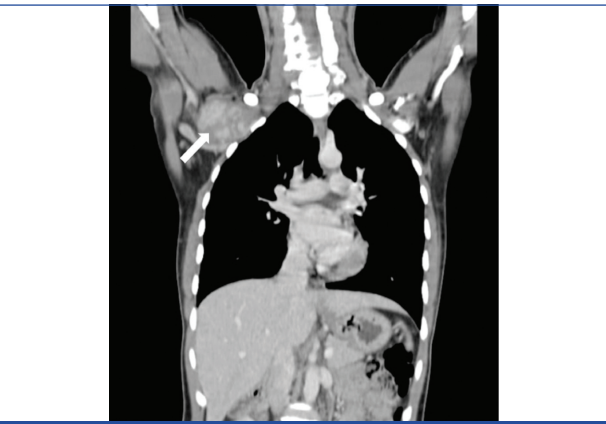

[Table/Fig-2]: Coronal CECT image reveals a large heterogeneously enhancing mass in the right infraclavicular region (white arrow), extending from the clavicle to the upper chest wall, compressing the subclavian artery inferiorly.

Surgical excision of the right infraclavicular mass was performed under general anaesthesia. A linear incision was made approximately 2 cm below the right infraclavicular region, followed by meticulous dissection to expose the tumour. Intraoperatively, a well-defined mass measuring approximately 5×5×3 cm was identified. The lesion was found to be adherent to the subclavian vein and artery posteriorly, the medial cord medially, and it extended superiorly to the right clavicle. The lesion was vascular in origin, not neural, and was abutting but not encasing the nerves (medial cord of the brachial plexus). A careful dissection was undertaken to excise the

tumour while preserving the integrity of the surrounding neurovascular structures [Table/Fig-3a-c]. Haemostasis was achieved, the surgical site was closed in anatomical layers, and a sterile dressing was applied.

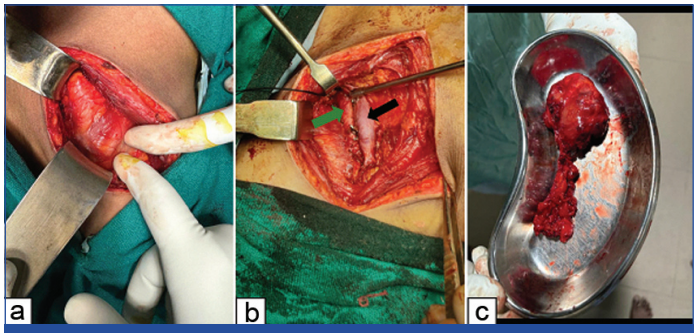

[Table/Fig-3]: a) Intraoperative image of tumour; b) Tumour base after excision with subclavian artery (green arrow) and subclavian vein (black arrow) and c) Excised tumour.

The HPE showed the tumour was composed of strands, cords, and nests of large endothelial cells with eosinophilic cytoplasm embedded in a myxohyaline stroma [Table/Fig-4]. The lesion was consistent with malignant haemangioendothelioma, and the margins were positive at the superior, inferior, and medial ends. The tumour exhibited features of histologic grade G1, with a mitotic rate of five mitoses per 10 high-power fields. There was no evidence of lymphovascular invasion or necrosis.

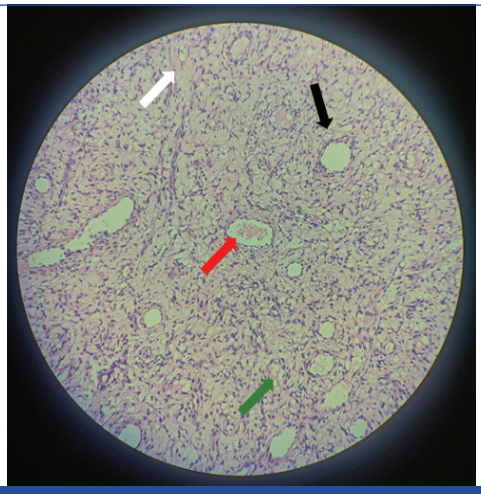

[Table/Fig-4]: Microscopic examination illustrating Red Blood Cells (RBCs) in lumen (red), intracytoplasmic vacuolation (green), myxohyaline stroma (white), and plump endothelial cells (black) (H&E, 20×).

The postoperative course was uneventful, and the patient remained stable throughout hospital stay. At the one-month follow-up, due to positive tumour margins, adjuvant external beam RT was initiated. RT was administered in a dose of 60 Gy in 30 fractions, with 2.0 Gy per fraction delivered in five fractions per week for six weeks. RT was well tolerated, and the patient was asymptomatic at the six-month follow-up.

DISCUSSION

Haemangioendotheliomas are vascular tumours exhibiting a broad biological spectrum, ranging from benign growths to low-grade malignant neoplasms [1]. Among them, malignant haemangioendotheliomas are an exceedingly rare subset of vascular sarcomas [2]. SCH is one of the several variants of haemangioendothelioma that typically occurs in the distal extremities. However, it has been reported in various unusual locations, including the head, neck, and trunk, accounting for less than 10% of cases [3]. SCH, particularly in the infraclavicular region, is highly uncommon and underreported [4].

Spindle cell haemangioma, initially designated as SCH by Weiss and Enzinger in 1986, is a rare benign vascular tumour exhibiting histological characteristics of both Kaposi's sarcoma and cavernous haemangioma [5]. SCH typically manifests as subcutaneous or cutaneous nodules in young adults, predominantly appearing in the subcutis or dermis of the distal extremities. It is infrequently located in deep soft tissues, particularly in regions such as the infraclavicular area [4,6]. The lesion demonstrates no gender predilection and occurs across a broad age range, with a peak incidence in the fourth decade of life [6]. In present case, the patient was a 32-year-old female, and the tumour was located in the deep soft tissues of the right infraclavicular region.

The pathogenesis and biological functioning of SCH are still unknown. Some researchers propose that it represents a benign or reactive neoplastic process, while others suggest it arises from thrombosis followed by recanalisation within an existing vascular lesion [7]. It can present as multiple or solitary lesions and has been linked with vascular disorders such as lymphedema, Maffucci's syndrome, Klippel-Trenaunay-Weber syndrome, superficial cutaneous lymphatic malformations, and epithelioid haemangioendothelioma [4]. Although the lesion is generally benign, it is known to recur locally; its rarity and histological similarity to other vascular tumours, such as angiosarcoma, hinder further diagnosis. In present case, the initial histopathology from a Tru-cut biopsy suggested a benign spindle cell lesion favoring neurofibroma, leading to a provisional misdiagnosis and conservative management initially.

Clinically, SCH is typically asymptomatic in the early stages and often presents as a slowly enlarging, painless mass. Symptoms such as paresthesia, localised swelling, or even neurological deficits may develop as the lesion grows and compresses surrounding structures. This non specific symptomatology can lead to misdiagnosis, particularly in deep or atypical locations [6,8]. In present case, the patient presented with gradually progressive swelling of the right upper limb and an infraclavicular mass, along with a tingling sensation around the elbow, leading to the initial misinterpretation as a nerve sheath tumour.

Imaging studies are pivotal in delineating the extent of lesions and their relationship with adjacent structures; however, they often lack specificity in confirming the nature of the tumour [9]. In present patient, chest MRI and ultrasound indicated a PNST. However, the final diagnosis depended on HPE, as imaging alone cannot definitively characterise the lesion [8]. SCH may mimic PNSTs due to its perivascular distribution and infiltrative growth, thus making early diagnosis difficult [10]. Literature suggests that patients with SCH present similarly to those with PNST-like lesions, highlighting the role of immunohistochemical differentiation (CD31+, ERG+) [11]. Kharazm P et al., reported a rare case of MPNST located in the carotid space that clinically mimicked a carotid body tumour; however, imaging suggested it was a paraganglioma, and it was confirmed as an MPNST on HPE [12]. In present case, despite detailed imaging, the definitive diagnosis of haemangioendothelioma was achieved only after complete excision and HPE; however, immunohistochemistry was not performed.

Differential diagnoses for SCH include Kaposi sarcoma, Kaposi-like haemangioendothelioma, cavernous haemangioma, epithelioid haemangioendothelioma, and intravascular papillary endothelial hyperplasia. SCH is distinguished from these conditions based on histological examination, demonstrating spindle cell features compared to epithelioid characteristics, as well as immunophenotypes {CD31/CD34 positivity and Human Herpesvirus (HHV)-8 negativity} [3]. Management strategies for SCH range from conservative surgery to interventions such as cryotherapy, laser ablation, systemic steroids, radiation, and interleukin-2 therapy [7]. Nevertheless, surgical excision remains the standard treatment for SCH [4]. In present patient, complete excision was performed via a right infraclavicular incision. Histopathology remains the gold standard for diagnosis. SCH exhibits features of cavernous vascular spaces interspersed with spindle cell proliferation, and the diagnosis may mimic malignant tumours [13,14]. In present case, microscopic examination was consistent with the findings of malignant haemangioendothelioma (spindle cell subtype).

Author (year)	Age/ Gender	Tumour location	Initial diagnosis/ Impression	Final diagnosis	Diagnostic modality	Management	Outcome
Savithri V et al., [4] (2022)	27/M	Lower lip (oral cavity)	Pyogenic granuloma/ Peripheral giant cell granuloma	Spindle cell haemangioma	Histopathology and immunohistochemistry (IHC: CD31+, CD34+)	Surgical excision	No recurrence at 2-year follow-up
Chen WJ et al., [9] (2022)	33/M	Sternum	Chondrosarcoma/ Metastatic tumour	Spindle cell haemangioma	Computed Tomography (CT), Magnetic Resonance Imaging (MRI), Histopathology (IHC: CD31+, ERG+)	Wide local excision	No recurrence (6-month follow-up)
Kharazm P et al., [12] (2024)	67/M	Neck (carotid region)	Carotid body tumour	Malignant peripheral nerve sheath tumour	CT Angiography, Contrast-enhanced CT, Histopathology (IHC: S100+, SOX10+)	Surgical resection+ Adjuvant chemo-Radiotherapy (RT)	Death at 11-month
Jot K et al., [13] (2022)	25/M	Mandibular labial vestibule (oral cavity)	Haemangioma/ Vascular malformation	Spindle cell haemangioma	Histopathology {Immunohistochemistry (IHC): CD31+, CD34+}	Surgical excision	No recurrence (8-month follow-up)
Akhtar K et al., [15] (2022)	58/M	Femur (presenting as pathological fracture)	Vascularised soft-tissue tumour	Spindle Cell Haemangioendothelioma (SCH)	X-ray, CT, Histopathology (IHC: CD31+)	Curettage+nailing	Healing observed (6-month follow-up)

[Table/Fig-5]: Review of literature showing spindle cell haemangioma in various body parts [4,9,12,13,15].

Postoperative management for haemangioendothelioma typically involves wound care, physiotherapy to maintain limb function, and close monitoring for signs of recurrence [9]. SCH has a benign, indolent course and a tendency to recur [15]. Recent studies suggest the use of postoperative radiotherapy and immunomodulatory agents in managing difficult-to-treat or recurrent haemangioendothelioma to reduce recurrence risk [9]. A review of the literature shows spindle cell haemangioma in various body parts [Table/Fig-5] [4,9,12,13,15].

CONCLUSION(S)

Malignant haemangioendothelioma is a rare vascular neoplasm that can present as a painless mass in the right infraclavicular region. It must be included in the differential diagnosis of soft tissue tumours presenting near major vascular structures, especially when initial imaging and biopsy findings are inconclusive. Given its deceptive presentation, early surgical excision with clear margins and thorough histopathological evaluation is essential for appropriate management.

Acknowledgement

The authors would like to thank Dr. Vikas S Sharma (MD), CEO of Maverick Medicorum® (India), for manuscript writing, editing, and submission.

REFERENCES

[1] McNab PM, Quigley BC, Glass LF, Jukic DM. Composite hemangioendothelioma and its classification as a low-grade malignancy. Am J Dermatopathol. 2013;35(4):517-22.
[2] Paulson KG, Ravi V, Rubin BP, Park M, Loggers ET, Cranmer LD, et al. Incidence, demographics, and survival of malignant hemangioendothelioma in the United States. Cancer Med. 2023;12(14):15101-06.
[3] Perkins P, Weiss SW. Spindle cell hemangioendothelioma. An analysis of 78 cases with reassessment of its pathogenesis and biologic behavior. Am J Surg Pathol. 1996;20(10):1196-204.
[4] Savithri V, Suresh R, Janardhanan M, Aravind T. Spindle cell haemangioma - Report of a rare entity. J Oral Maxillofac Pathol. 2022;26(3):424.
[5] Das KD, Ghosh K, Kar C, Gharami RC, Chakraborty S, Bhattacharyya A. Spindle cell hemangioendothelioma: Rare clinical entity. Indian J Dermatol. 2015;60(5):509-11.
[6] Winter A, Siu A, Jamshidi A, Malawer M, Sherman JH. Spindle cell hemangioendothelioma of the sacrum: Case report. J Neurosurg Spine. 2014;21(2):275-78.
[7] Gbolahan OO, Fasina O, Adisa AO, Fasola OA. Spindle cell hemangioma: Unusual presentation of an uncommon tumor. J Oral Maxillofac Pathol. 2015;19(3):406.
[8] Yang J, Li H, Gao J. A case of extramedullary subdural spindle cell hemangioendothelioma of the thoracic spinal cord treated curatively with radiation therapy. Heliyon. 2023;9(7):e18149.
[9] Chen WJ, Wu CY, Zhang LP, Hou LK, Dong ZW, Huang Y, et al. Spindle cell hemangioma in the sternum: Report of a case. Zhonghua Bing Li Xue Za Zhi. 2022;51(9):899-901.
[10] Rodriguez FJ, Folpe AL, Giannini C, Perry A. Pathology of peripheral nerve sheath tumors: Diagnostic overview and update on selected diagnostic problems. Acta Neuropathol. 2012;123(3):295-319.
[11] Mani A, Bajpai M, Sabnis SL. Immunohistochemical analysis of oral spindle cell hemangioma. J Dent (Shiraz). 2025;26(2):194-98.
[12] Kharazm P, Noruzi S, Aghili A, Zarbakhsh A, Azarhoosh R, Maghsudloo F. Malignant peripheral nerve sheath tumor mimicking carotid body tumor, a rare case report and review of literature. Int J Surg Case Rep. 2024;124:110406.
[13] Jot K, Manchanda S, Roychoudhury A, Mishra D. Rare case of spindle cell haemangioma of oral cavity. BMJ Case Rep. 2022;15(6):e249600.
[14] Tosios KI, Gouveris I, Sklavounou A, Koutlas IG. Spindle cell hemangioma (hemangioendothelioma) of the head and neck: Case report of an unusual (or underdiagnosed) tumor. Oral Surg Oral Med Oral Pathol Oral Radiol Endod. 2008;105(2):216-21.
[15] Akhtar K, Ara A, Gupta S, Fahim M. Spindle cell hemangioendothelioma presenting as fracture femur - A rare case presentation. Ann Oncol Res Ther 2022;2:45-48.

PARTICULARS OF CONTRIBUTORS:
1. Junior Resident, Department of General Surgery, Jawaharlal Nehru Medical College, Acharya Vinoba Bhave Rural Hospital, Sawangi, Meghe, Wardha, Maharashtra, India.
2. Professor and Head, Department of General Surgery, Jawaharlal Nehru Medical College, Acharya Vinoba Bhave Rural Hospital, Sawangi, Meghe, Wardha, Maharashtra, India.
3. Professor, Department of Pharmacology, Jawaharlal Nehru Medical College, Acharya Vinoba Bhave Rural Hospital, Sawangi, Meghe, Wardha, Maharashtra, India.
4. Junior Resident, Department of Pathology, Krishna Institute of Medical Sciences, Karad, Maharashtra, India.
5. Junior Resident, Department of Pathology, Jawaharlal Nehru Medical College, Acharya Vinoba Bhave Rural Hospital, Sawangi, Meghe, Wardha, Maharashtra, India.

NAME, ADDRESS, E-MAIL ID OF THE CORRESPONDING AUTHOR:
Dr. Ashish Jivani,
Junior Resident, Department of General Surgery, Jawaharlal Nehru Medical College, Acharya Vinoba Bhave Rural Hospital, Sawangi, Meghe,
Wardha-442001, Maharashtra, India.
E-mail: ajpatidar017@gmail.com

PLAGIARISM CHECKING METHODS: [Jain H et al.]
- Plagiarism X-checker: Jun 09, 2025
- Manual Googling: Jul 24, 2025
- iThenticate Software: Jul 26, 2025 (10%)

ETYMOLOGY: Author Origin

EMENDATIONS: 6

AUTHOR DECLARATION:
- Financial or Other Competing Interests: None
- Was informed consent obtained from the subjects involved in the study? Yes
- For any images presented appropriate consent has been obtained from the subjects. Yes

Date of Submission: **Jun 01, 2025**
Date of Peer Review: **Jun 23, 2025**
Date of Acceptance: **Jul 29, 2025**
Date of Publishing: **Oct 01, 2025**